



PATIENT

Luna Clark

SPECIES

Canine

BREED

Terrier

SEX

Female Spayed

AGE

~9 years

PRESENTING CLINICAL SIGNS

History: Heart murmur has progressed; grade 5/6.
-Current medications: Pimobendan 3.75mg PO q12h, Benazepril 5mg PO q24h.
-CBC/Chem/Lytes/T4 performed in Feb. 2021 WNL.
Pertinent previous echo findings (8/2021): mod MR, mod to severe LAE, mild/mod TR

RADIOGRAPHIC FINDINGS *NOTE: Images submitted for supplemental cardiac information only.
Cardiomegaly with LA enlargement. No obvious evidence of CHF.

ECHOCARDIOGRAM FINDINGS

2D, m-mode, color flow and doppler imaging is available. Diffuse thickening of mitral valve leaflets (anterior>posterior) with prolapse into the left atrial lumen. Moderate eccentric mitral regurgitation with moderate left atrial dilation. Normal MR velocity. Mildly increased LV diameter with hyperdynamic myocardial function. The tricuspid valve is thickened with septal prolapse and mild tricuspid regurgitation. Normal velocity. Normal right atrial and ventricular diameter. The pulmonic and aortic valves are normal in morphology and mobility. Normal pulmonic and aortic outflow velocities. No aortic or pulmonic insufficiency. No pericardial or pleural effusion noted. No cardiac tumors observed.

CARDIAC CHART

WEIGHT

24lbs

INTERPRETED BY

Maggie Machen Lamy,
DVM, DACVIM
(Cardiology)

IMAGING PERFORMED BY

Loetitia St-Jacques,
LVT/RVT

HOSPITAL NAME

Pine Creek Veterinary
Clinic

REFERRING VET

Dr. Nolet

INVOICE

20958

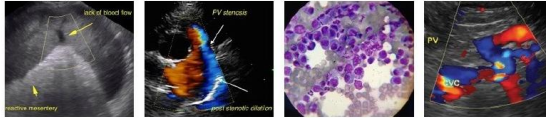
DATE

9/9/21

CANINE CARDIAC PARAMETERS	MR VMAX (m/s)	TR VMAX (m/s)	LA/AO (Boon method)	LA/AO (Heart Base; Swe)	FS (%)	EF (%)	EPSS (cm)
NORMAL PARAMETER	4.5-5.5	<2.7	1.3	<1.6	28-40	40-100	<0.6
PATIENT	5.9	2.7	NM	1.6	42	74	NM
CANINE CARDIAC PARAMETERS	HR (BPM)	AV VMAX (m/s)	PV MAX (m/s)	BODY WEIGHT (kg)	LA 2D short axis Base view (cm)	LVIDd Avg; 2D and m-mode short axis (cm)	LVIDs Avg; 2D and m-mode short axis (cm)
NORMAL PARAMETER	50-100	0.7-1.7	0.7-1.6	BELOW	BELOW	BELOW	BELOW
PATIENT	61	1.5	0.7	10.9	2.8	4.0	2.3
*Normal chamber parameters expressed as a mean value (SD)				3	1.27 (5.3)	2.46 (2.46)	1.36 (5.5)
BODY WEIGHT DEPENDENT PARAMETERS				5	1.40 (4.5)	2.74 (5.2)	1.60 (4.7)
<i>*Note: All measurements based upon multi-modal images and methods. An average value is reported.</i>				10	1.50 (3.8)	3.27 (3.5)	2.06 (3.1)
				15	1.83 (2.0)	3.71 (2.4)	2.43 (2.1)
				20	2.02 (1.9)	4.14 (2.2)	2.80 (2.0)
				25	2.18 (2.4)	4.48 (2.9)	3.10 (2.5)
				30	2.33 (3.3)	4.83 (3.9)	3.39 (3.4)
				35	2.48 (4.3)	5.17 (5.0)	3.69 (4.5)
				40	2.62 (5.2)	5.48 (6.1)	3.96 (5.4)
				50	2.88 (7.1)	6.07 (8.3)	4.46 (7.4)

INTERPRETATION OF THE FINDINGS & FURTHER RECOMMENDATIONS

Chronic degenerative valve disease causing moderate mitral and trace tricuspid regurgitation. Moderate left atrial enlargement indicates there is relatively low risk for imminent complication, however risk for progression to spontaneous congestive heart failure in the future is elevated. No



PATIENT

Luna Clark

additional issues are identified. Compared to what is described in the prior study, these findings are similar, with minimal evidence of progression despite an increase in murmur intensity.

SPECIES

Canine

Given the risk for progression and results of the EPIC trial, Pimobendan is indicated in this patient as below. Assessment of progression in the future will help predict long term outcome; however, prognosis is guarded at this stage (B2).

BREED

Terrier

Omega fatty acid supplementation and mild salt restriction may also be of some long term benefit. Monitor for development of a progressive cough, labored breathing, exercise intolerance or collapse episodes.

SEX

Female Spayed

Anesthetic risk is considered mildly elevated. Cardiac protective drug choices (opioid/benzodiazepine premedication, Propofol or alfaxalone induction, iso or sevo gas) are recommended. Monitor for arrhythmias, hypotension, and hypoxia both intra and post-operatively and intervene as necessary. Judicious IV fluid rates are recommended to avoid fluid overload. Avoid heart rate stimulating drugs such as atropine unless clinically indicated.

AGE

~9 years

Plan: Baseline BP recommended. Continue Pimobendan and Benazepril as prescribed.

WEIGHT

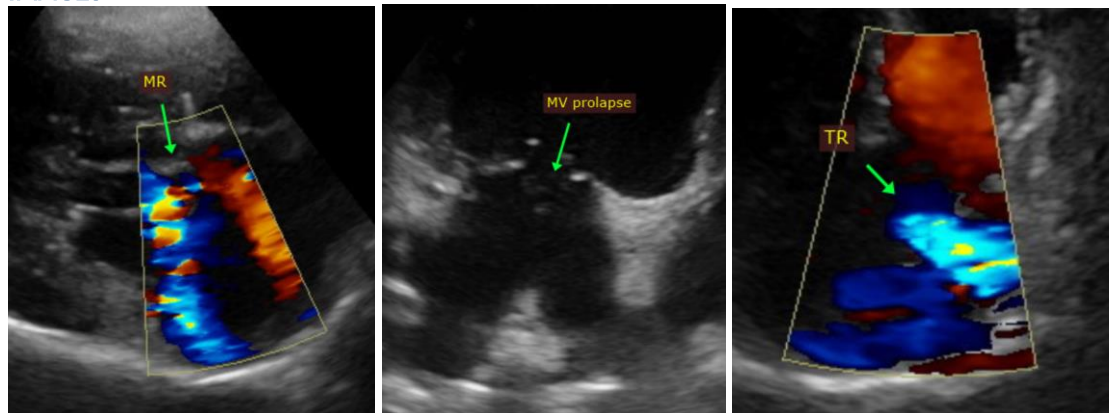
24lbs

Recommend monitor for progression with a recheck echocardiogram in 6 months, sooner if any development of clinical signs.

INTERPRETED BY

Maggie Machen Lamy,
DVM, DACVIM
(Cardiology)

IMAGES



IMAGING PERFORMED BY

Loetitia St-Jacques,
LVT/RVT

The information and recommendations provided are based on the images presented by the referring veterinarian. No evaluation can be communicated regarding pathology that was not visible in the image/video clips provided.

HOSPITAL NAME

Pine Creek Veterinary
Clinic

Thank you for this referral. This report was generated using transcription software, and minor dictation errors may be present. If the clinical or image interpretation does not parallel your findings or if I can be of any further assistance please contact me.

REFERRING VET

Dr. Nolet

INVOICE

20958

Maggie Machen Lamy, DVM
Diplomate of the American College of Veterinary Internal Medicine (Cardiology)
info@sonopath.com

DATE

9/9/21